

Refractory Noninfectious Anterior Uveitis Associated With Systemic Mastocytosis

Hani S. Al-Mezaine, MD; Saleh Al-Obeidan, MD; Malak M. Al-Hakeem, MD; Ahmed M. Abu El-Asrar, MD

ABSTRACT

A 10-year-old boy with biopsy-proven systemic mastocytosis presented with bilateral nongranulomatous anterior uveitis associated with high intraocular pressure. Anterior chamber paracentesis was performed for cytological evaluation, which demonstrated monocytes and macrophages but no evidence of mast cells. His uveitis was partially controlled with frequent topical steroid drops and weekly oral methotrexate therapy. The glaucoma was controlled with topical antiglaucoma medications in the right eye. Deep sclerectomy was required in the left eye to control the intraocular pressure. To the best of the authors' knowledge, this is the first report of such an association.

INTRODUCTION

Mastocytosis is a disorder characterized by an abnormal proliferation of normal, active tissue mast cells. The primary event responsible for mast cell proliferation in mastocytosis is largely unknown. However, it is believed that normal mast cell development requires an interaction between mast cell growth factor and c-kit receptors, which are expressed by mast cells at their different developmental stages. Dereglulation of the c-kit receptors could, theoretically, produce disordered mast-cell proliferation.¹

The prevalence of mastocytosis in the general population is unknown, but it is generally considered to be an "orphan disease" (200,000 or fewer people in the United States). Mastocytosis occurs in

all races and there is no sex predilection. The peak incidence is during infancy and early childhood, with a second peak in middle age.²

Mastocytosis encompasses a wide range of disorders; the clinical signs vary and depend on the local overproliferation and accumulation of mast cells in different organs. The episodic release of mast cell mediators leads to the wide range of symptoms associated with mastocytosis. Although most commonly seen in the skin, mastocytosis may also involve bones, the hematopoietic system, the gastrointestinal tract, lymph nodes, the cardiovascular system, and the central nervous system. Symptoms and signs include pruritus, facial flushing, bronchoconstriction, headache, and syncope. The most common systemic findings are anemia, leukocytosis, and hepatosplenomegaly.³

We present a case of refractory noninfectious nongranulomatous anterior uveitis associated with systemic mastocytosis. To the best of our knowledge, this is the first report of such an association.

CASE REPORT

A 10-year-old boy presented in October 2003 with a 2-week history of redness, pain, and photophobia in both eyes. He was diagnosed as having systemic mastocytosis at the age of 4 months, at which time he presented with diarrhea, hepatosplenomegaly, and typical skin lesions. The diagnosis was confirmed by the demonstration of mast cell hyperplasia on skin biopsy (Figure).

On presentation, the uncorrected visual acuity was

From the Department of Ophthalmology (HSA-M, SA-O, AMAE-A) and the Department of Obstetrics and Gynecology (MMA-H), College of Medicine, King Saud University, Riyadh, Saudi Arabia.

Originally submitted December 14, 2008. Accepted for publication April 13, 2009. Posted online August 22, 2009.

The authors have no financial or proprietary interest in the materials presented herein.

Address correspondence to Hani S. Al-Mezaine, MD, Anterior Segment Division, King Abdulaziz University Hospital, P. O. Box 230387, Riyadh 11321, Saudi Arabia.

doi: 10.3928/01913913-20090918-01

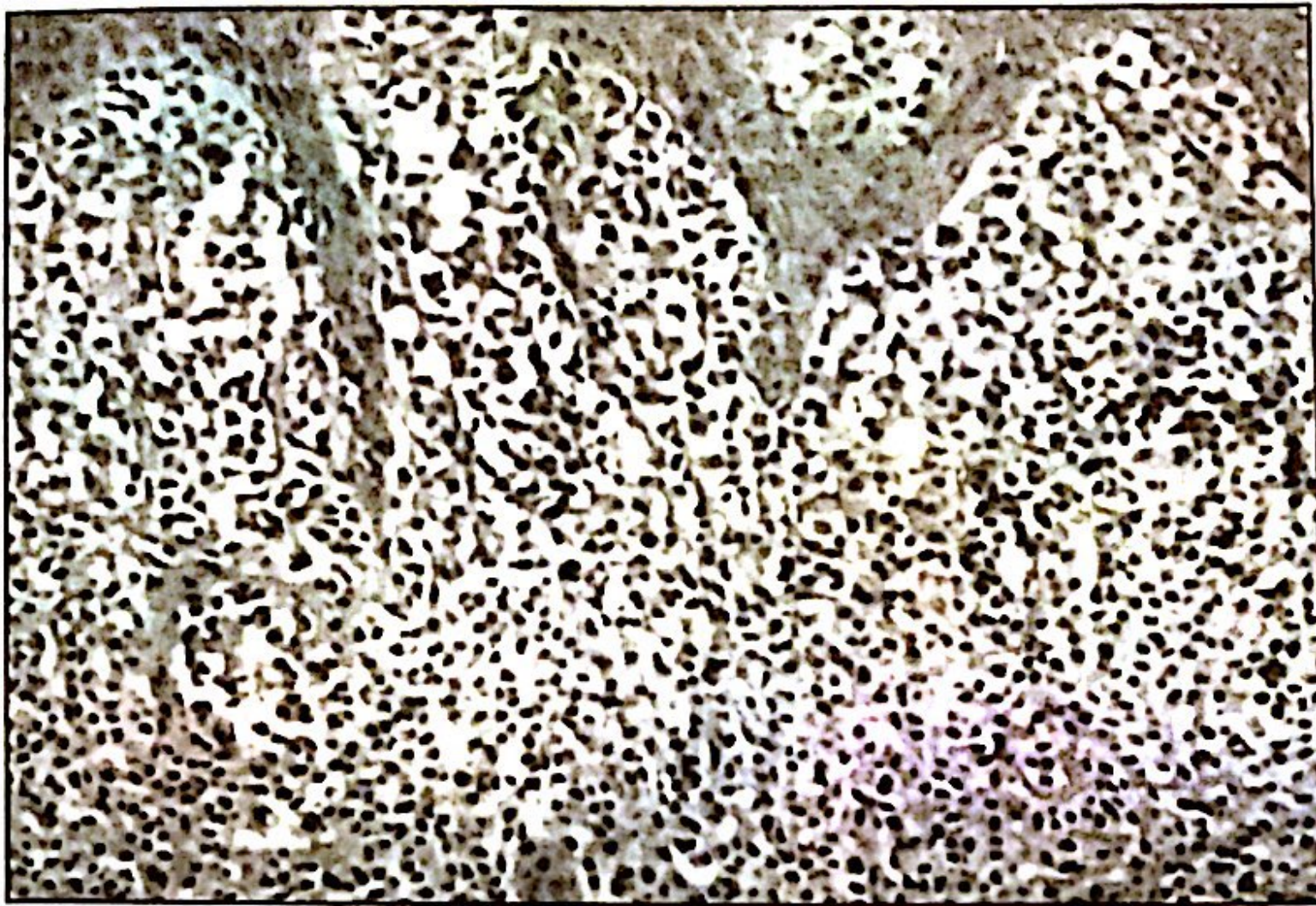


Figure. Histopathology of the skin from the buttock area showed a dense infiltrate of the upper one-third of the dermis with cells containing an intensely eosinophilic cytoplasm and small, round, uniform hyperchromatic nuclei, which are consistent with mastocytosis.

20/20 in both eyes. The intraocular pressure (IOP) was 28 mm Hg in the right eye and 30 mm Hg in the left eye. Slit-lamp examination revealed a circumcornea injection, as well as an anterior chamber reaction of 4-cells and 2+ flare in both eyes. No keratic precipitates, iris nodules, or posterior synechiae were detected in either eye. Both lenses were clear and the posterior segment evaluation was within normal limits in both eyes.